

Physician Information:

Jack Smith, M.D.
Sunshine Dermatology Center
100 Main Street
Anytown, NC 22222
Phone: 919-999-9999

PATHOLOGY REPORT

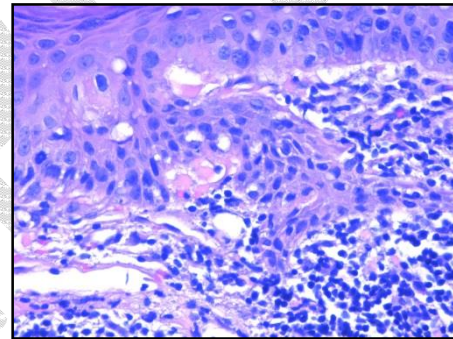
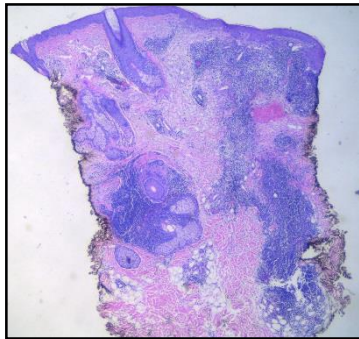
Patient:	Smith, Kelly K.	Case Number:	D15-00008
DOB/Age:	1/10/1988 (27 years)	Sex: F	Date Collected: 01/12/2015
MRN:	12456	Date Received: 01/12/2015	Date Reported: 01/14/2015
Phone #:	919-563-1485		

CLINICAL HISTORY:
rule out connective tissue disease

DIAGNOSIS:

Skin, Left Parietal Scalp (Punch Biopsy):
CHRONIC CUTANEOUS (DISCOID) LUPUS ERYTHEMATOSUS

Images are for illustrative purposes only and should not be used as diagnostic tools



A superficial and deep perivascular and perifollicular infiltrate is present.

Scattered necrotic keratinocytes (colloid bodies) are noted along the dermoepidermal junction

MICROSCOPIC DESCRIPTION:

The sections show a dense superficial and deep perivascular and perifollicular lymphocytic inflammatory cell infiltrate with epidermal atrophy, follicular plugging, vacuolar change, thickened basement membrane zone, and increased dermal mucin.

GROSS DESCRIPTION:

Received in formalin and labeled with the patient's name and "Left Parietal Scalp" is punch biopsy of skin and subcutis measuring 0.4 x 0.4 x 1.0 cm. The specimen is bisected and submitted entirely in 1 cassette labeled A. Due to the loss of elastic tension and to formalin shrinkage, the measurements in the laboratory description may be less than those taken at the time of surgical removal. gm/GJS

CPT CODES: 88305
ICD CODES: 695.4

ELECTRONICALLY SIGNED BY:

Garron J. Solomon, M.D.

Garron J. Solomon, M.D.
01/14/2015 at 2:35 pm