

## PATHOLOGY REPORT

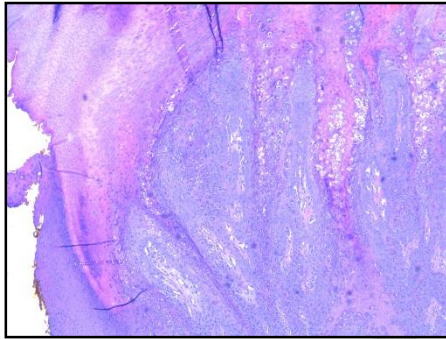
<b>Patient:</b>	<b>Doe, Jane R.</b>	<b>Case Number:</b>	<b>D15-00004</b>
DOB/Age:	12/10/1950 (64 years)	Sex: F	Date Collected: 01/12/2015
MRN:	12456	Date Received: 01/12/2015	Date Reported: 01/14/2015
Phone #:	919-563-1485		

**CLINICAL HISTORY:**  
rule out wart

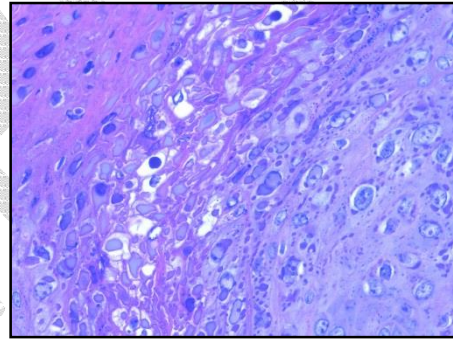
### DIAGNOSIS:

Skin, Right Heel (Punch):  
**VERRUCA VULGARIS, MYRMECIAL TYPE**

Images are for illustrative purposes only and should not be used as diagnostic tools



Marked papillomatosis and hyperkeratosis are seen here.



There is marked viral cytopathic change with large eosinophilic cytoplasmic inclusions.

### MICROSCOPIC DESCRIPTION:

The sections show hyperkeratosis, parakeratosis, papillomatosis and acanthosis with enlarged keratohyaline granules and eosinophilic cytoplasmic inclusions.

### GROSS DESCRIPTION:

Received in formalin and labeled with the patient's name and "Right Heel" is a shave biopsy of skin measuring 0.6 x 0.5 x 0.4 cm. The specimen is inked in black, bisected and entirely submitted in 1 cassette labeled A. Due to the loss of elastic tension and to formalin shrinkage, the measurements in the laboratory description may be less than those taken at the time of surgical removal. gm/GJS

**CPT CODES:** 88305  
**ICD CODES:** 078.10

ELECTRONICALLY SIGNED BY: *Garron J. Solomon, M.D.*

**Garron J. Solomon, M.D.**  
01/14/2015 at 2:35 pm